



**PATIENT**

Yogi Russo

**SPECIES**

Canine

**BREED**

Schnauzer

**SEX**

Male Neutered

**AGE**

14 years

**WEIGHT**

17.6lbs

**INTERPRETED BY**

Maggie Machen  
Lamy, DVM  
DACVIM (Cardiology)

**IMAGING PERFORMED BY**

Pamela Harrigan,  
RDCS

**HOSPITAL NAME**

Wignall Animal  
Hospital

**REFERRING VET**

Dr. Harvey

**INVOICE**

28443

**DATE**

1/19/23

**PRESENTING CLINICAL SIGNS**

History: Recheck echo. History chronic valvular disease- Stage B1. Doing well clinically. Grade III/VI heart murmur.

-Pertinent previous echo findings (6/16/22 MML): LA 2.0 cm, LA:Ao 1.4, LV 2.4 cm, mild LAE, mild MR, mild TR (2.7m/s) \*Sedated with Torbugesic\*

**ECHOCARDIOGRAM FINDINGS**

2D, m-mode, color flow and Doppler imaging is available.

**Left ventricle:** The LV diameter is normal with adequate myocardial function. LV wall thicknesses are normal.

**Left atrium:** The left atrium is mildly dilated.

**Mitral valve:** The mitral valve is diffusely thickened with significant prolapse into the left atrial lumen. Mild eccentric mitral regurgitation with a normal velocity.

**Aortic valve/aorta:** The aortic valve is normal in morphology and mobility. Normal aortic outflow velocity; laminar flow. No aortic insufficiency.

**Right ventricle:** Normal right ventricular diameter and morphology indicating no overt evidence of pulmonary arterial hypertension.

**Right atrium:** Normal RA dimension.

**Tricuspid valve:** The tricuspid valve appears mildly thickening with septal prolapse and trace tricuspid regurgitation.

**Pulmonic valve/pulmonary artery:** The pulmonic valve is normal in morphology and mobility. No pulmonic insufficiency. Normal RVOT velocity; laminar flow.

**Pericardium/other:** No pericardial or pleural effusion noted. No obvious cardiac masses.

**Heart rhythm:** ECG reveals a sinus rhythm with an average HR of 150bpm.

**2-Dimensional Measurements**

Ao diam (cm)	1.5
LA diam (cm)	1.9
LA:Ao (Swe)	1.3
IVS thickness (cm)	0.6
LVID diastole (cm)	2.5
PW thickness (cm)	0.6
LVID systole (cm)	0.9
FS (%)	62

**Doppler Measurements**

PV Vmax (m/s)	0.74
AoV Vmax (m/s)	1.2
MR Vmax (m/s)	6.0
TR Vmax (m/s)	NM
TR PG (mmHg)	NA

**INTERPRETATION OF THE FINDINGS**

Chronic degenerative valve disease persists with overall stability. Mild mitral and trace tricuspid regurgitation are unchanged without progressive left or right heart enlargement. No concurrent issues such as systolic dysfunction or pulmonary hypertension are noted in this study. Assessment of progression in the future will help predict long term prognosis, which is highly variable at this stage (B1).

**RECOMMENDATIONS**

- Given these findings, no cardiac medications are clearly indicated.
- Omega fatty acid supplementation and mild salt restriction may be of some long-term benefit.
- Anesthetic risk is considered mild if needed. Cardiac protective drug choices (opioid/benzodiazepine premedication, propofol or alfaxalone induction, isoflurane



**PATIENT**

Yogi Russo

**SPECIES**

Canine

**BREED**

Schnauzer

**SEX**

Male Neutered

**AGE**

14 years

**WEIGHT**

17.6lbs

**INTERPRETED BY**

Maggie Machen Lamy, DVM  
 DACVIM (Cardiology)

**IMAGING PERFORMED BY**

Pamela Harrigan, RDCS

**HOSPITAL NAME**

Wignall Animal Hospital

**REFERRING VET**

Dr. Harvey

**INVOICE**

28443

**DATE**

1/19/23

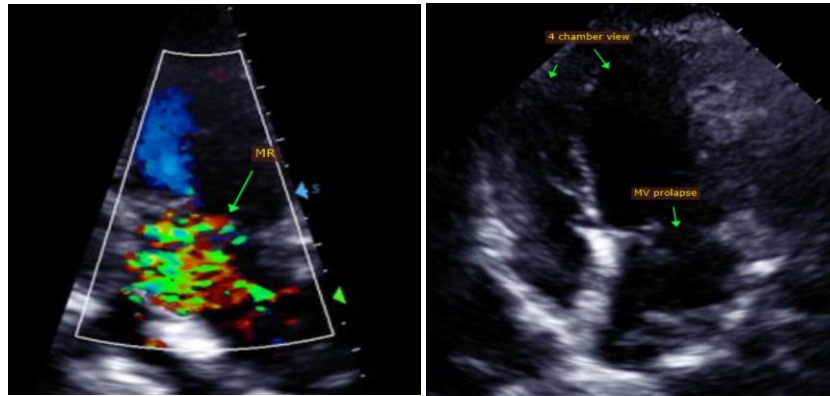
gas) are recommended. Pre-oxygenate for 5-10 minutes prior to induction. Monitor for arrhythmias, hypotension, and hypoxia both intra and post-operatively and intervene as necessary. Mild IV fluid restriction is recommended to avoid fluid overload. Avoid heart rate stimulating drugs such as atropine unless clinically indicated.

- Monitor for development of a cough, labored breathing, exercise intolerance or collapse episodes.

**PLAN**

- Recommend conservative monitoring with a recheck echocardiogram in 6 months, sooner if any development of clinical signs.

**IMAGES**



The information and recommendations provided are based on the images presented by the referring veterinarian. No evaluation can be communicated regarding pathology that was not visible in the image/video clips provided.

Thank you for this referral. This report was generated using transcription software, and minor dictation errors may be present. If the clinical or image interpretation does not parallel your findings or if I can be of any further assistance, please contact me.

**Maggie Machen Lamy, DVM**  
 Diplomate of the American College of Veterinary Internal Medicine (Cardiology)  
 info@sonopath.com

Echocardiogram performed by: Pamela Harrigan, RDCS  
 Pet Animal Ultrasound Service ([4paus.com](http://4paus.com))